












## CASE REPORT

# ALVR109, an off-the-shelf partially HLA matched SARS-CoV-2-specific T cell therapy, to treat refractory severe COVID-19 pneumonia in a heart transplant patient: Case report

Katalin Martits-Chalangari<sup>1,2</sup>  | Cedric W. Spak<sup>1,3</sup>  | Medhat Askar<sup>1,2,3</sup>  |  
 Aaron Killian<sup>1,2</sup>  | Tammy L. Fisher<sup>1,2</sup>  | Ercem Atillasoy<sup>4</sup>  | William L. Marshall<sup>4</sup>  |  
 David McNeel<sup>4</sup>  | Michael D. Miller<sup>4</sup>  | Susan K. Mathai<sup>1,2,3</sup>  |  
 Robert L. Gottlieb<sup>1,2,3,5</sup> 

<sup>1</sup>Baylor University Medical Center, Dallas, Texas, USA

<sup>2</sup>Baylor Scott & White Research Institute, Dallas, Texas, USA

<sup>3</sup>Texas A&M Health Science Center, Dallas, Texas, USA

<sup>4</sup>AlloVir, Cambridge, Massachusetts, USA

<sup>5</sup>TCU and University of North Texas Health Science Center, Fort Worth, Texas, USA

## Correspondence

Robert L. Gottlieb, Center for Advanced Heart and Lung Disease, Baylor University Medical Center, Dallas, TX, USA.  
 Email: robert.gottlieb@bswhealth.org

## Funding information

AlloVir

An unvaccinated adult male heart transplant recipient patient with recalcitrant COVID-19 due to SARS-CoV-2 delta variant with rising nasopharyngeal quantitative viral load was successfully treated with ALVR109, an off-the-shelf SARS-CoV-2-specific T cell therapy. Background immunosuppression included 0.1 mg/kg prednisone, tacrolimus, and mycophenolate mofetil 1 gm twice daily for historical antibody-mediated rejection. Prior therapies included remdesivir, corticosteroids, and tocilizumab, with requirement for high-flow nasal oxygen. Lack of clinical improvement and acutely rising nasopharyngeal viral RNA more than 3 weeks into illness prompted the request of ALVR109 through an emergency IND. The day following the first ALVR109 infusion, the patient's nasopharyngeal SARS-CoV-2 RNA declined from 7.43 to 5.02 log<sub>10</sub> RNA copies/ml. On post-infusion day 4, the patient transitioned to low-flow oxygen. Two subsequent infusions of ALVR109 were administered 10 and 26 days after the first; nasopharyngeal SARS-CoV-2 RNA became undetectable on Day 11, and he was discharged the following day on low-flow oxygen 5 weeks after the initial diagnosis of COVID-19. The clinical and virologic improvements observed in this patient following administration of ALVR109 suggest a potential benefit that warrants further exploration in clinical trials.

## KEYWORDS

antibiotic: antiviral, clinical research/practice, heart transplantation/cardiology, immunobiology, infection and infectious agents—viral: SARS-CoV-2/COVID-19, infectious disease

**Abbreviations:** AMR, antibody-mediated rejection; COVID-19, coronavirus disease 2019; EIND, emergency investigational new drug application; HLA, human leukocyte antigen; SARS-CoV-2, severe acute respiratory syndrome coronavirus-2.

This is an open access article under the terms of the Creative Commons Attribution-NonCommercial-NoDerivs License, which permits use and distribution in any medium, provided the original work is properly cited, the use is non-commercial and no modifications or adaptations are made.

© 2021 The Authors. *American Journal of Transplantation* published by Wiley Periodicals LLC on behalf of The American Society of Transplantation and the American Society of Transplant Surgeons

## 1 | INTRODUCTION

Transplant patients, including heart transplant recipients, are at heightened risk for severe complications and death from COVID-19.<sup>1</sup> Some immunosuppressive agents used to prevent graft rejection make patients more vulnerable to opportunistic infections, including viral infections such as SARS-CoV-2.<sup>2,3</sup> Moreover, the comorbidities frequently found in this population greatly increase the likelihood that SARS-CoV-2 infections will have adverse outcomes. In a case series involving 99 heart transplant recipients with COVID-19, nearly two thirds (64%) required hospitalization, and 15 (15%) died of complications of COVID-19.<sup>1</sup> Other case series of heart transplant patients with severe COVID-19 report fatality rates as high as 30%.<sup>3-5</sup>

We report the case of a heart transplant recipient with intractable severe-to-critical COVID-19 treated with ALVR109, an investigational off-the-shelf T cell therapy consisting of partially HLA-matched, polyclonal (CD4+ and CD8+) SARS-CoV-2-specific T cells expanded from the peripheral blood of convalescent healthy donors seropositive for SARS-CoV-2.<sup>6,7</sup> ALVR109 T cells were generated by in vitro stimulation with immunodominant SARS-CoV-2 spike, membrane, nucleocapsid, NSP4, and AP7a proteins.<sup>8</sup> Although ALVR109 was developed to target the reference strain of SARS-CoV-2 (NC\_045512.2) originally identified in Wuhan, China, its recognition of multiple antigens reduces the risk of virus immune escape. In vitro, ALVR109 has shown the ability to target clinically important variants of SARS-CoV-2, including Alpha, Beta, Gamma, Delta, Epsilon, and Kappa.<sup>8</sup>

## 2 | CASE DESCRIPTION

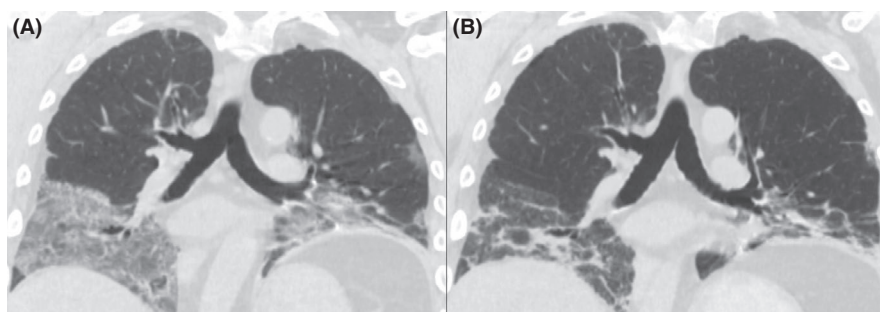
A 47-year-old unvaccinated male heart transplant recipient with a history of antibody-mediated rejection completed a 5-day course of remdesivir for moderate COVID-19 secondary to B.1.617.2 (Delta) variant of SARS-CoV-2 and was discharged without hypoxemia. Two days later, he experienced progressively worsening fatigue,

shortness of breath, low-grade fever, and cough with clear sputum and re-presented with acute respiratory distress syndrome. A CT scan of the chest showed bilateral mid and lower lung pulmonary opacities, consistent with COVID-19 pneumonia (Figure 1A). The patient required oxygen support by high-flow nasal cannula and pulse-dosed corticosteroids. Tocilizumab was administered on the following day for acutely worsening hypoxemia. At that time, the patient was IgG seropositive for anti-nucleocapsid IgG and indeterminate for IgM and IgG for all other targets including total spike, receptor binding domain (RBD), S1, and S2 (LABScreen COVID Plus, One Lambda).

The patient was 5½ years posttransplant and, due to a history of antibody-mediated rejection (AMR) of his cardiac allograft, outpatient maintenance immunosuppression included the triple regimen of prednisone 7.5 mg daily (0.1 mg/kg/day), tacrolimus (goal trough 5–8 ng/ml), and mycophenolate mofetil 1 gm twice a day. To balance the competing risks from AMR history with the risks of antimetabolite prescription in COVID-19, mycophenolate mofetil was reduced to 500 mg twice daily upon re-admission for Covid-19.

After the failure of repeated attempts to wean the patient off high-flow oxygen support, we requested and received approval from our local institutional review board and the US FDA to administer ALVR109 under a single-patient Emergency Investigational New Drug application. Signed informed consent was obtained. Historical HLA typing of the patient and heart donor informed the selection of a suitable line of ALVR109 for the patient that matched at 4 of 8 HLA alleles. A total of three doses of ALVR109 (manufactured at the Center for Cell and Gene Therapy GMP facility, Baylor College of Medicine) were provided to administer a dose of  $2 \times 10^7$  cells once every  $14 \pm 4$  days.

On day 26 from first hospital presentation, despite interval seroconversion for all IgM and IgG targets except IgM anti-S2 (that remained indeterminate), the quantitative nasopharyngeal SARS-CoV-2 viral load was actively rising to  $\log_{10}$  7.42 copies/ml. Given the evidence of renewed viral replication and ongoing symptoms, the first dose of ALVR109 was administered. The infusion was uneventful with no signs of cytokine release syndrome or anaphylaxis



**FIGURE 1** CT Scans of Patient's Lungs before and after Treatment. (A) Representative coronal image of patient's CT scan of the chest without contrast performed 12 days after initial diagnosis of COVID-19 infection, illustrating severe mid-and lower-lung predominant bilateral ground glass opacities consistent with SARS-CoV-2 infection. (B) Representative coronal image of patient's CT scan of the chest without contrast performed 1 month after initial diagnosis, illustrating evolution of COVID-19 pneumonia; though mid- and lower-lung predominant ground glass opacities are still present, they are interspersed now with reticular and consolidative changes

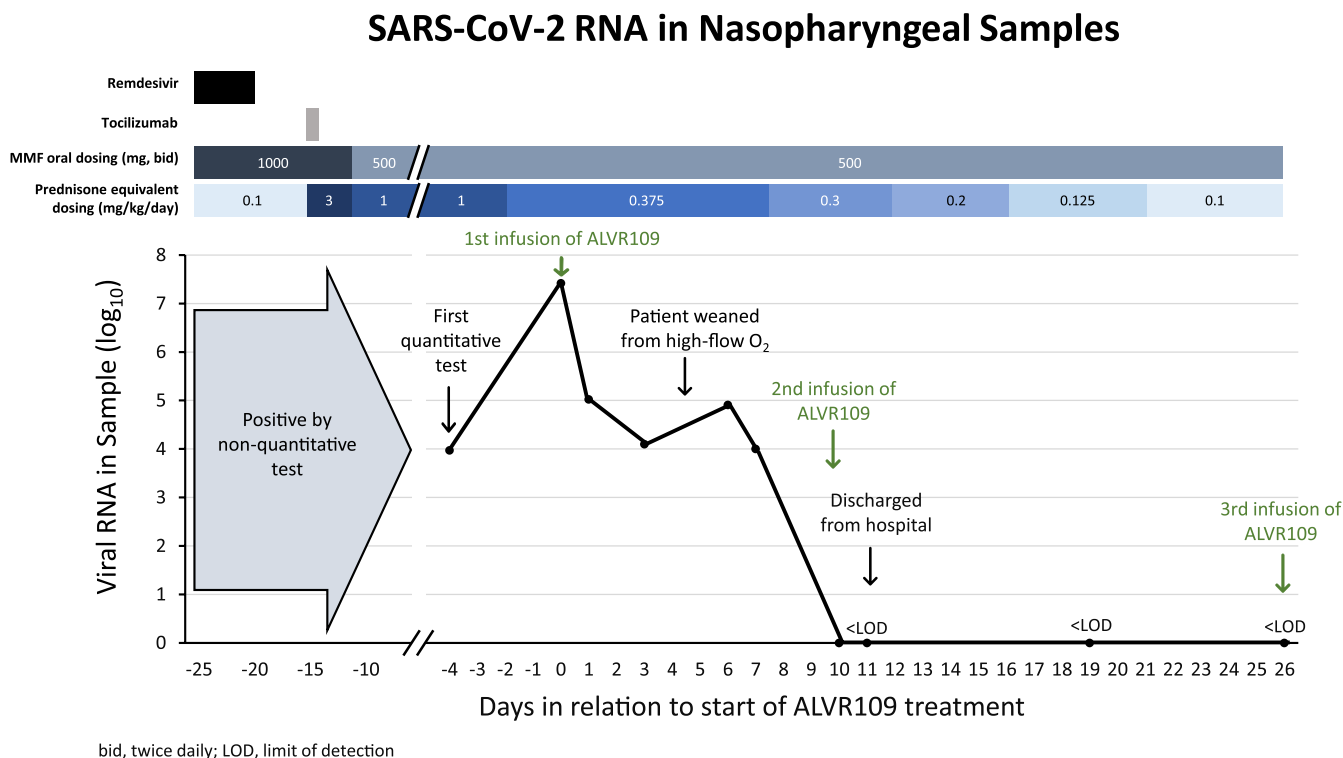
and no clinically significant changes in vital signs or adverse symptoms. By the following day, the patient's nasopharyngeal viral load declined to  $\log_{10}$  5.02 copies/ml. As shown in Figure 2, the patient's viral load continued to decrease, with some dynamic variability, and his clinical status improved in the following days. On post-infusion day 10, the date of the second infusion of ALVR109, the patient's nasopharyngeal SARS-CoV-2 viral load became durably undetectable. The patient was discharged the day after the second infusion on low-flow oxygen support, having achieved a second negative quantitative nasopharyngeal PCR. Given a persistent lower-lobe lung organizing pneumonia (Figure 1B), the patient continued to use nasal cannula as needed (3 L/min) and returned for a third infusion of ALVR109. Although the patient's viral load remained undetectable since the second ALVR109 infusion, he had not returned to baseline (pre-COVID) pulmonary status, highlighting the importance of early therapeutic intervention.

Given competing needs for corticosteroids for COVID-19 and related organizing pneumonia, balanced with the risk of corticosteroids attenuating the effect of the virus-specific T-cell therapy, the prednisone-equivalent corticosteroid dose that had been acutely pulsed at 1–3 mg/kg/day was stepped down to 0.5 mg/kg/day in preparation for ALVR109, lowered to 0.375 mg/kg/day upon first infusion, and lowered further to 0.3 mg/kg/day by the second infusion. After the final infusion, the patient's prednisone dosage was returned to the pre-COVID dose of 0.1 mg/kg/day. A week after discharge, the patient no longer met the criteria for supplemental oxygen on ambulatory 6-min walk testing.

### 3 | DISCUSSION

The armamentarium against COVID-19 now includes a range of treatment options. For early outpatient use, there are three different anti-SARS-CoV-2 monoclonal antibody products. For inpatient use, there is the RNA-dependent RNA polymerase inhibitor remdesivir, corticosteroids for those with hypoxemia, and possibly additional anti-inflammatory agents.<sup>9</sup> Nevertheless, there remains a significant unmet medical need for interventions that can benefit higher-risk patients as well as those who have not responded to existing treatment modalities. The need for agents with novel mechanisms of action is made more urgent by the continuing emergence of new viral variants that may be resistant to available treatments. This unmet need is especially acute in immune-compromised patients such as those with a history of stem cell or solid organ transplantation who are dependent on immune-suppressive regimens, as well as cancer patients receiving chemotherapy. Some therapeutic strategies that involve untargeted immune stimulation may increase the risk of organ rejection and cytokine storm.

Accumulating evidence indicates that T cells play an important role in the immune response to SARS-CoV-2 infection.<sup>10–13</sup> Over 80% of hospitalized patients with COVID-19 are lymphopenic,<sup>14</sup> with reduced CD8+ and CD4+ T-cell counts that correlate negatively with survival.<sup>10,11</sup> Reduced T-cell counts are particularly prevalent in older COVID-19 patients and those admitted to the intensive care unit.<sup>10</sup> In organ transplantation recipients, the use of immunosuppressive agents targeting cellular immune signaling pathways



**FIGURE 2** SARS-CoV-2 Nasopharyngeal RNA Over Time. Initial diagnosis of SARS-CoV-2 infection was made using a non-quantitative nasopharyngeal test. The black line represents nasopharyngeal SARS-CoV-2 RNA over time since the first quantitative test was administered 4 days before ALVR109 treatment. LOD, limit of detection

inhibits rejection mediated by the patient's immune response and is critical to graft survival.<sup>15</sup> These patients are at higher risk of severe or fatal COVID-19 due to reduced T cell counts.<sup>1,4,5</sup> Several groups are exploring the possibility of treating COVID-19 using the adoptive transfer of SARS-CoV-2-specific T cells from convalescent donors.<sup>16-18</sup> This work is based on decades of research on the use of adoptive VSTs for the treatment of refractory and opportunistic infections in immunocompromised patients, such as those who have undergone transplantation.<sup>19-21</sup> The present case is the first time such a therapy has been used to treat a solid-organ transplant recipient with COVID-19 due to SARS-CoV-2 infection.

ALVR109 is designed to arrest the progression of COVID-19 by eradicating SARS-CoV-2 virus-infected cells by supplying SARS-CoV-2-specific T cells. ALVR109 was developed employing an approach that has been successfully used to make virus-specific T cell products for treating or preventing viral infections in other contexts. Posoleucel (ALVR105), which is made up of T cells specific for opportunistic infections that occur following allogeneic stem cell or solid organ transplants, has been shown to be safe and effective against Epstein-Barr virus, adenovirus, cytomegalovirus, BK virus, and human herpesvirus 6.<sup>22</sup> Like posoleucel, ALVR109 is intended for patients matched at a minimum of 2 HLA alleles to the patient and/or donated organ. Given that it is restricted to memory T cells specifically targeting SARS-CoV-2, ALVR109 does not produce a generalized boosting of immune function, which may reduce the risk of off-target effects in transplant patients, such as rejection, graft versus host disease, and cytokine storm. However, many questions concerning the management of COVID-19 in transplant patients remain unanswered, including best practices for the adjustment of maintenance immunosuppression.

In this report, we have described the case of an immunocompromised patient with persistent SARS-CoV-2 delta variant infection who was treated with ALVR109, an off-the-shelf SARS-CoV-2-specific T cell therapy. The elimination of the infection following the first infusion of ALVR109 is suggestive of a robust virologic response, but confirmation of the safety and efficacy of ALVR109 in patients with COVID-19 will require further evaluation in randomized, controlled clinical trials.

## ACKNOWLEDGMENTS

The authors thank the patient, the clinical nurses who helped him recuperate, and the convalescent donors of the virus-specific T cell lines that have been used to create ALVR109. Funding for this trial was provided by AlloVir.

## DISCLOSURE

The authors of this manuscript have conflicts of interest to disclose as described by the *American Journal of Transplantation*. Ercem Atillasoy, William Marshall, David McNeel, Michael D. Miller are employees of, and hold stock in, AlloVir. Robert L. Gottlieb has received research funds from Gilead Sciences and consulting fees from Gilead Science, Eli Lilly, GSK, Roche, and Johnson & Johnson. Baylor Scott & White Research Institute received funding in exchange for

consulting Dr Gottlieb did for Kinevant (Roivant) Sciences. The other authors have no conflicts of interest to disclose.

## DATA AVAILABILITY STATEMENT

The data that support the findings of this study are available on request from the corresponding author. The data are not publicly available due to privacy or ethical restrictions.

## ORCID

Katalin Martits-Chalangari  <https://orcid.org/0000-0002-2423-865X>

Cedric W. Spak  <https://orcid.org/0000-0002-3916-0998>

Medhat Askar  <https://orcid.org/0000-0003-2633-9363>

Aaron Killian  <https://orcid.org/0000-0002-7477-5998>

Tammy L. Fisher  <https://orcid.org/0000-0002-5117-1390>

Ercem Atillasoy  <https://orcid.org/0000-0001-7370-3311>

William L. Marshall  <https://orcid.org/0000-0002-6662-0582>

David McNeel  <https://orcid.org/0000-0001-8294-8492>

Michael D. Miller  <https://orcid.org/0000-0002-4929-2257>

Susan K. Mathai  <https://orcid.org/0000-0002-5899-8083>

Robert L. Gottlieb  <https://orcid.org/0000-0001-8376-8709>

## REFERENCES

1. Genuardi MV, Moss N, Najjar SS, et al. Coronavirus disease 2019 in heart transplant recipients: risk factors, immunosuppression, and outcomes. *J Heart Lung Transplant*. 2021;40(9):926-935.
2. Boyarsky BJ, Werbel WA, Avery RK, et al. Antibody response to 2-dose SARS-CoV-2 mRNA vaccine series in solid organ transplant recipients. *JAMA*. 2021;325(21):2204-2206.
3. Latif F, Farr MA, Clerkin KJ, et al. Characteristics and outcomes of recipients of heart transplant with coronavirus disease 2019. *JAMA Cardiol*. 2020;5(10):1165-1169.
4. Iacovoni A, Boffini M, Pidello S, et al. A case series of novel coronavirus infection in heart transplantation from 2 centers in the pandemic area in the North of Italy. *J Heart Lung Transplant*. 2020;39(10):1081-1088.
5. Bottio T, Bagozzi L, Fiocco A, et al. COVID-19 in heart transplant recipients: a multicenter analysis of the Northern Italian outbreak. *JACC Heart Fail*. 2021;9(1):52-61.
6. Vasileiou S, Kuvalekar M, Workineh A, et al. Using allogeneic, off-the-shelf, SARS-CoV-2-specific T cells to treat high risk patients with COVID-19 [abstract]. *Blood*. 2020;136(Suppl 1):5.
7. Vasileiou S, Kuvalekar M, Workineh A, et al. Allogeneic, off-the-shelf, SARS-CoV-2-specific T cells to treat high-risk patients with COVID-19 [abstract]. *Transplant Cell Ther*. 2021;27:S348-S349.
8. Vasileiou S, Kuvalekar M, Workineh A, et al. Allogeneic, off-the-shelf, SARS-CoV-2-specific T cells demonstrate reactivity against emerging variant strains [abstract]. *Open Forum Infect Dis*. 2021;8(Suppl 1):S27.
9. COVID-19 Treatment Guidelines Panel. Coronavirus Disease 2019 (COVID-19) Treatment Guidelines. National Institutes of Health. Available at <https://www.covid19treatmentguidelines.nih.gov/> Accessed 9/24/21
10. Diao BO, Wang C, Tan Y, et al. Reduction and functional exhaustion of T cells in patients with Coronavirus Disease 2019 (COVID-19). *Front Immunol*. 2020;11:827.
11. Zheng M, Gao Y, Wang G, et al. Functional exhaustion of antiviral lymphocytes in COVID-19 patients. *Cell Mol Immunol*. 2020;17(5):533-535.

12. Chen Z, Wherry EJ. T cell responses in patients with COVID-19. *Nat Rev Immunol*. 2020;20(9):529-534.
13. Harrington P, Doores KJ, Radia D, et al. Single dose of BNT162b2 mRNA vaccine against severe acute respiratory syndrome coronavirus-2 (SARS-CoV-2) induces neutralising antibody and polyfunctional T-cell responses in patients with chronic myeloid leukaemia. *Br J Haematol*. 2021;194:999-1006.
14. Guan W-J, Liang W-H, Zhao YI, et al. Comorbidity and its impact on 1590 patients with Covid-19 in China: a nationwide analysis. *Eur Respir J*. 2020;55(5):2000547.
15. Wojciechowski D, Wiseman A. Long-term immunosuppression management opportunities and uncertainties. *Clin J Am Soc Nephrol*. 2021;16(8):1264-1271.
16. Guerreiro M, Aguilar-Gallardo C, Montoro J, et al. Adoptive transfer of ex vivo expanded SARS-CoV-2-specific cytotoxic lymphocytes: a viable strategy for COVID-19 immunosuppressed patients? *Transpl Infect Dis*. 2021;23(4):e13602.
17. Pérez-Martínez A, Mora-Rillo M, Ferreras C, et al. Phase I dose-escalation single centre clinical trial to evaluate the safety of infusion of memory T cells as adoptive therapy in COVID-19 (RELEASE). *EClinicalMedicine*. 2021;39:101086.
18. Basar R, Uprety N, Ensley E, et al. Generation of glucocorticoid-resistant SARS-CoV-2 T cells for adoptive cell therapy. *Cell Rep*. 2021;36(3):109432.
19. Leen AM, Bollard CM, Mendizabal AM, et al. Multicenter study of banked third-party virus-specific T cells to treat severe viral infections after hematopoietic stem cell transplantation. *Blood*. 2013;121(26):5113-5123.
20. Mancini N, Marrone L, Clementi N, et al. Adoptive T-cell therapy in the treatment of viral and opportunistic fungal infections. *Future Microbiol*. 2015;10:665-682.
21. Nelson AS, Yalamarthy N, Yong MK, et al. Beyond antivirals: virus-specific T-cell immunotherapy for BK virus haemorrhagic cystitis and JC virus progressive multifocal leukoencephalopathy. *Curr Opin Infect Dis*. 2021;34:627-634.
22. Tzannou I, Papadopoulou A, Naik S, et al. Off-the-shelf virus-specific T cells to treat BK virus, human herpesvirus 6, cytomegalovirus, Epstein-Barr virus, and adenovirus infections after allogeneic hematopoietic stem-cell transplantation. *J Clin Oncol*. 2017;35:3547-3557.

**How to cite this article:** Martits-Chalangari K, Spak CW, Askar M, et al. ALVR109, an off-the-shelf partially HLA matched SARS-CoV-2-specific T cell therapy, to treat refractory severe COVID-19 pneumonia in a heart transplant patient: Case report. *Am J Transplant*. 2021;00:1-5. doi:[10.1111/ajt.16927](https://doi.org/10.1111/ajt.16927)